

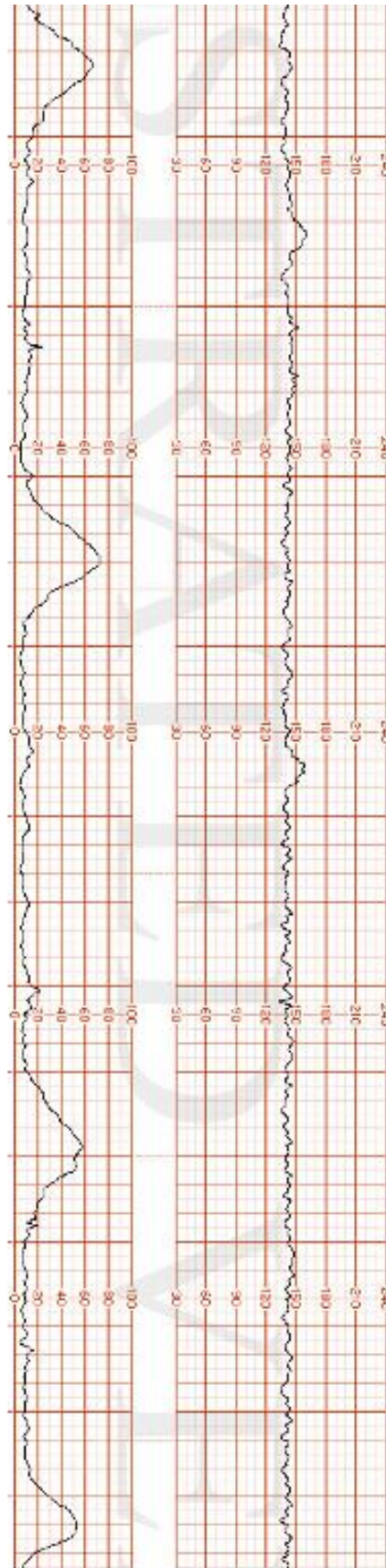
Case Briefing

It's a Wednesday evening and the hospital is staffed by you (on-call for obstetrics), one other physician (on-call to ER), two RNs, and an RPN. The other physician, a RN, and the RPN are currently busy in the ER. The second RN is available to help with labour and delivery.

You get called into the delivery room where you find a young woman entering in visible distress accompanied by her mother. She appears to be full-term and has been having abdominal pain for the past five hours. She has no known allergies, her family history and past medical history are insignificant, and her general physical exam is otherwise normal.

Patient Chart					
Name: Jane Taylor	Age: 29	Gender: F	Weight: 75 kg	Height: 163 cm	GA: 40 Weeks
Temp: 36.9	HR: 95 bpm	BP: 125/85	RR: 18/min	O₂Sat: 99%	GCS: 15
Presenting complaint: Abdominal pain.					

Fetal Heart Rate (FHR) Tracing #1



Reference(s):

Retrieved July 20, 2023, from <https://www.illustratedverdict.com/template-fetal-strips-iv-fetal-strip-library-from-courses>