

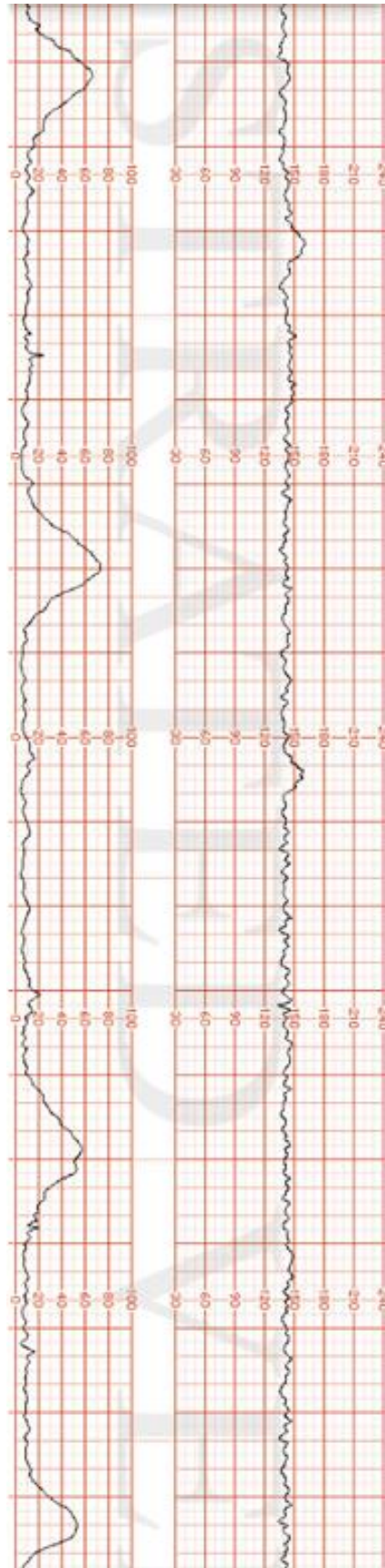
Case Briefing

It's a Tuesday afternoon and you are on call for obstetrics in a rural 1A hospital (no local cesarean section capabilities), with the nearest urban centre being 500km away.

A 27-year-old G1P0 female, Brittney Scott, presents to the emergency department complaining of mild back pain since last night and feeling like she is unable to control her bladder, stating she feels like she is "leaking." Brittney is 32+3 weeks gestational age. She has not been receiving any prenatal care since her initial appointment confirming the pregnancy at 10 weeks gestational age. Brittney has a history of IV substance use which has continued throughout the pregnancy. She currently smokes approximately 1 pack of cigarettes per week.

Patient Chart					
Name: Brittney Scott	Age: 27	Gender: F	Weight: 59 kg	Height: 168 cm	GA: 32+3 Weeks
Temp: 36.7	HR: 102 bpm	BP: 119/77	RR: 22/min	O₂Sat: 97%	GCS: 15
Presenting complaint: Vaginal discharge and a low, dull backache since 1900 yesterday evening.					

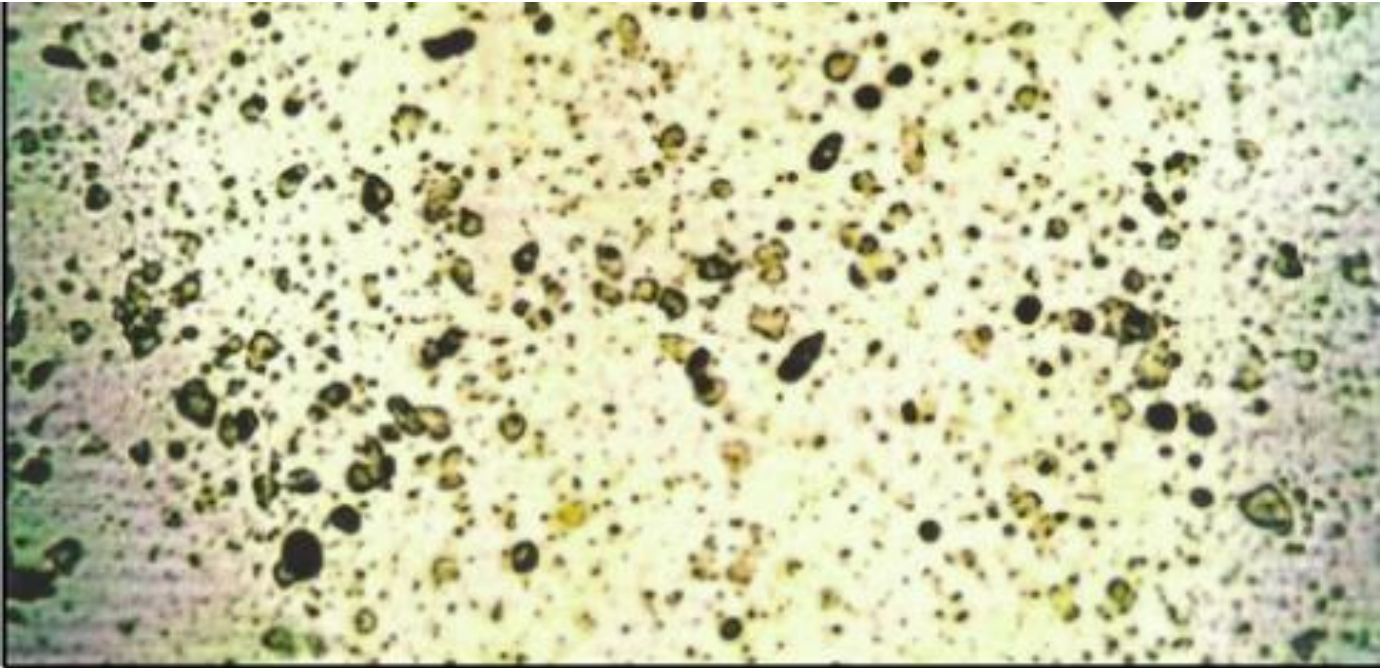
Fetal Heart Rate (FHR) Tracing #1



Reference(s):

Retrieved September 16, 2023, from <https://www.illustratedverdict.com/template-fetal-strips-iv-fetal-strip-library-from-courses>

Microscope / Fern Test Result:



Reference(s):

Dias Nunes, R., Traebert, E., Seemann, M, Traebert, J. (2020). Evaluation of simple and low-cost diagnostic tests for premature rupture of membranes. *Clin. Exp. Obstet. Gynecol*, 47(2), 287–290. <https://doi.org/10.31083/j.ceog.2020.02.4986>

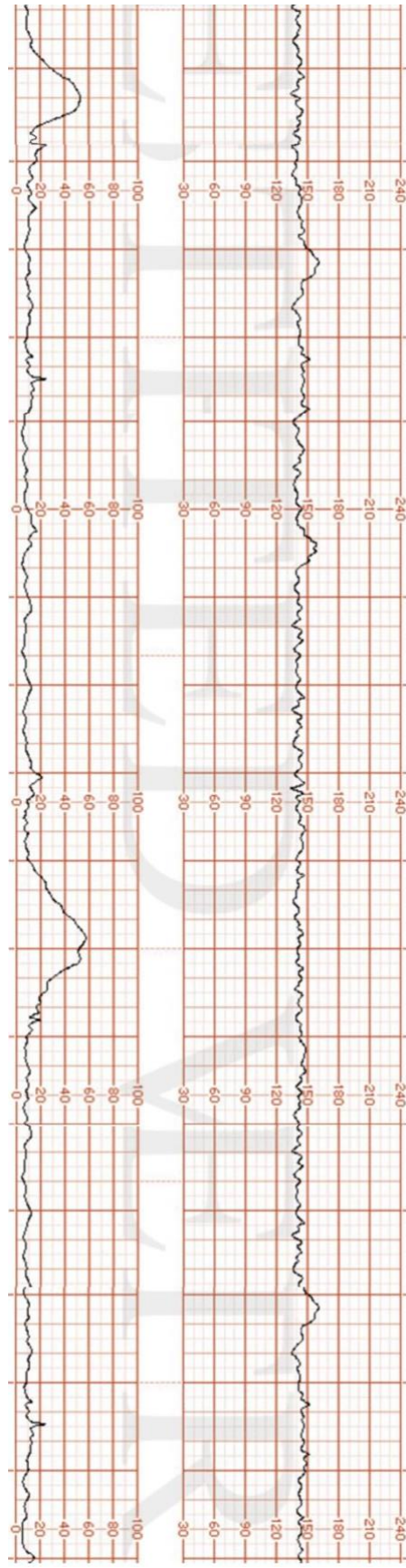
Nitrazine pH Test Result:



Reference(s):

Retrieved September 12, 2023 from <https://oacapps.med.jhmi.edu/OBGYN-101/Text/Abnormal%20L&D/PROM.htm>

Fetal Heart Rate (FHR) Tracing #2



Reference(s):

Retrieved September 16, 2023, from <https://www.illustratedverdict.com/template-fetal-strips-iv-fetal-strip-library-from-courses>